

Original Research

Measurement of serum interleukin 17 level in patients with genital warts before and after intralesional tuberculin injection

Mohamed Azab^{1,*}, Mohamed M. El-Shabrawy², Essam R. O. Abu Nafea³, Hesham A. Nada⁴

¹Department of Andrology, Sexology and STDS, Faculty of Medicine, Suez Canal University, 41511 Ismailia, Egypt

²Department of Clinical pathology, Faculty of Medicine, Suez Canal University, 41511 Ismailia, Egypt

³Department of Dermatology and Venereology, Dermatology and leprosy Mansoura Hospital, Ministry of health and population, 11049 Mansoura, Egypt

⁴Department of Dermatology, Venereology and Andrology, Faculty of Medicine, Suez Canal University, 41511 Ismailia, Egypt

*Correspondence: Dr.Mohamed_azab@yahoo.com (Mohamed Azab)

Submitted: 28 May 2021 Accepted: 3 August 2021 Published: 27 August 2021

Abstract

Introduction and aim: Genital wart infection is a distressing sexually transmitted infection that causes marked fear and stress to both males and females. Tuberculin Purified protein derivative (PPD) injection is an upcoming safe and effective modality for the treatment of genital warts. Interleukin 17 (IL-17) was found to be lower in wart patients than controls. This study aimed at measurement of serum level of IL-17 in genital warts patients before and after PPD injection. **Patients and methods:** The study was carried out as case-control interventional study on 63 patients (37 males and 26 females) with genital warts attending Dermatology and Andrology Clinics, faculty of medicine, Suez Canal University hospitals. 50 controls were enrolled in the study. All patients have injected 10 tuberculin units of PPD intradermally in the mother or largest warts every 2 weeks till 6 sessions. Serum level of IL-17 was measured by Sandwich ELISA technique to all patients before and after PPD injection and to all control subjects. **Results:** The mean age of patients was 30.8 years, the mean duration of warts was 4.73 months, the mean number of warts was 9.76 warts and 14.3% of patients experienced side effects to PPD. (58.7%) of patients were completely recovered from warts. Mean serum IL-17 was 81.1 ± 64.2 pg/mL versus 118.9 ± 93.8 pg/mL in genital wart patients versus controls respectively ($P < 0.05$) and 81.1 ± 64.2 pg/mL versus 107.1 ± 66.8 pg/mL before and after PPD injection respectively ($P < 0.05$). **Conclusion:** IL-17 serum level was significantly lower in genital wart patients than normal controls. IL-17 serum level had been increased significantly after PPD intralesional injection than pretreatment levels and significantly related to clinical response to PPD. IL-17 suggested having a role in the clinical efficacy of PPD in the treatment of genital warts.

Keywords: Genital warts; Tuberculin PPD; Interleukin 17

1. Introduction

Genital warts are common sexually transmitted infections that affect sexually active males and females. Genital warts are caused by human papilloma virus (HPV) which has more than 100 different types. Type 6 and 11 are the most common types. HPV is transmitted through direct skin contact with an infected individual, usually during sex [1].

Genital warts have no specific systemic therapy available to eradicate HPV. Treatment strategies are different and dependent on the site, size, and number of warts, physician experience, available instruments, and patient's predilection. Treatments are either ablative (excision, resection, vaporization, coagulation, or laser therapy), minimally ablative (Podophyline, keratolytics, caustics, cryotherapy, or immunomodulators), injection immunotherapy, or HPV vaccines. Most of the treatments used can cause hyper or hypo-pigmentation, irritation, pain and permanent scarring [2–7].

Purified protein derivative (PPD) is one of the most commonly used substances in wart immunotherapy as it can produce a delayed-type hypersensitivity reaction against viral particles at injection sites and distant sites which cause complete and safe wart eradication [8]. Intralesional PPD is

associated with the production of Th1 cytokines such as interleukins, 4, 5, 8 & 12, INF γ and TNF α , which stimulate cytotoxic and natural killer cells that produce a destructive immune reaction against HPV [9].

Body defense against human papilloma virus depends on solid functioning cellular immune response including T cell and natural killer cell cytotoxicity. Defect in the immune system is suggested in patients with extensive, resistant, or recurrent warts [10]. Interleukin 17 (IL-17) is a group a pro-inflammatory cytokines that are involved in inflammation, autoimmune reactions, and body defense against bacteria. There are six members in this family: IL-17 A, IL-17 B, IL-17 C, IL-17 D, IL-17 E (or IL25), and IL-17 F. IL-17 A and IL-17 F are the most nearly related members of this group. IL-17 has been incriminated in allergic rhinitis, bronchial asthma, and many chronic autoimmune diseases including psoriasis and systemic sclerosis [11].

Serum level of IL-17 was found to be decreased in patients with cutaneous warts than normal controls; this denotes that IL-17 plays an important role in body defense against HPV [12]. IL-17 was found also to be decreased in patients with recalcitrant warts than patients with ordinary warts [13].



Till to our knowledge, no available clinical studies highlighted the relationship between PPD immunotherapy and the level of serum IL-17 in genital wart patients. In the current work, we aimed at measuring the level of IL-17 in genital wart patients before and after PPD Injection and in comparison to normal controls and to find out if IL-17 has an actual role as a pro-inflammatory mediator in the pathogenesis of HPV infection and its eradication by PPD immunotherapy or not.

2. Patients and methods

This study was a prospective case-control pre and post-interventional study carried out on male and female patients with a diagnosis of genital warts presented to Dermatology, Venerology and Andrology Clinics, Faculty of Medicine, Suez Canal University, during the period from June 2018 to May 2019.

Two groups were included in the study:

Group 1: 63 patients diagnosed with genital warts (37 males and 26 females) were injected with PPD. Group 2: 50 age-matched controls (30 males and 20 females) aged 18–50 years.

The primary endpoint of the study was to measure IL-17 in patients with genital warts before and after intralesional tuberculin PPD injection. Secondary endpoints were measurement of IL-17 in patients with genital warts in comparison to normal controls and assessment of the efficacy of PPD injection in the treatment of genital warts.

2.1 Patient's selection

Patient selection was done randomly from patients with genital warts accepted to participate in the study according to planned inclusion and exclusion criteria. Inclusion criteria included male or female patients aged more than 18 years old with genital warts for more than 3 months diagnosed by a trained dermatologist or andrologist. Exclusion criteria included patients treated for any type of warts in the last 3 months before the study, patients receiving any other therapeutic modality for warts during the study, immunocompromised patients, patients with active tuberculosis, pregnant and lactating females, and patients with systemic diseases that affect IL-17 serum level e.g., acute febrile illness, rheumatoid arthritis, asthma, systemic lupus erythematosus, psoriasis and multiple sclerosis.

2.2 Control group

Control groups were chosen randomly from normal volunteers or relatives to the studied patients. They should be free of any types of warts or medical conditions that affect the serum level of IL-17.

2.3 Medical history and examination

All the studied patients were subjected to complete history, general examination for any systemic medical diseases, and local genital examination for the site, number, size, distribution of warts, and for any other genital dermatological conditions.

2.4 Intralesional tuberculin PPD injection

63 patients with diagnosis of genital warts exposed to intralesional tuberculin PPD injection. Tuberculin test was done first to detect sensitization to PPD. The test was performed by injection of 0.1 mL of tuberculin PPD intradermally in the left forearm. Injection should create a well-defined white bleb at the injection point measured about 10 mm in diameter. The test was read 48–72 hours after injection and considered positive for sensitization by induration with or without erythema [14]. All sensitized patients have then injected 10 tuberculin units of PPD intradermal in the mother or largest warts every 2 weeks till 6 sessions [8]. Non-sensitized patients were excluded from the study and shifted to another method of treatment.

Clinical assessment was done every session by clinical examination and photographing to check the clinical response, patients feedback, and adverse effects to therapy.

Patients were divided according to the clinical response: responders, who had complete clearance of all warts after 6 sessions of PPD injection, and non-responders, who had no response or with incomplete clearance of warts after of 6 sessions of PPD injection [15].

The most commonly occurred side effects were local pain at the site of injection, edema, systemic symptoms, erythema, swelling, and post-inflammatory hypopigmentation or hyperpigmentation. These side effects happened in minority of patients and were treated symptomatically by topical and systemic analgesics and anti-inflammatory medications (i.e., Paracetamol, Diclofenac sodium, Ketorolofen, or Topical steroids). In all patients, these effects didn't lead to discontinuation of the study.

Non-responders were then re-examined by the researchers and another management plan was carried out till complete cure.

At the beginning of the study, 11 patients were excluded due to failure of sensitization to PPD vaccine. During the study 14 patients were excluded due to drop off from follow up. Excluded patients were replaced by other new patients and the study continued on the 63 patients mentioned.

Clinical recurrence of warts in responders was assessed during the 3 months after the last injection.

2.5 Measurement of serum IL-17 level

Serum IL-17 level was measured using double-antibody sandwich enzyme-linked immunosorbent assay (ELISA) using IL-17A KIT (LS-F24837, Lifespan Biosciences, Seattle, WA, USA). Unit of measurement was

Pico-gram per milliliter (pg/mL). The detection range was 5–500 pg/mL. IL-17 Measurement was done on all patients before and after PPD injection (63 Patients) and to all control subjects (50 persons).

2.6 Ethical considerations

The study was approved by Ethical Committee Board of the Faculty of Medicine, Suez Canal University. Ethical Committee approval number was 3487; date 9/4/2018. Written informative medical consent was signed by all patients and controls before participation in the study.

2.7 Statistical analysis

Statistical analysis was done using IBM® SPSS® Statistics version 25 (IBM® Corp., Armonk, NY, USA). Numerical data (e.g., age of patient, number & duration of genital warts and serum level of IL-17) was expressed as mean and standard deviation or median and range as appropriate. Correlations were done using the student *T* test and Mann Whitney test. The significance of the obtained results was judged at the 0.05 level.

3. Results

This study was carried out on 63 patients and 50 controls to measure the serum levels of IL-17 in patients with genital warts before and after intralesional PPD injection. The mean age of studied patients was 30.8 ± 14.8 years versus 31.7 ± 12.9 years in controls. Male patients were 57.1% of patients while female patients were 42.9%. The majority of participants were married, living in urban areas, and non-smokers Table 1.

A study of the characteristics of genital warts in studied patients revealed that the mean duration of infection was 4.73 ± 5.07 months, a mean number of warts was 9.76 ± 22.32 warts. The order of affected regions in the genital tract by warts was External genitalia, pubic, perianal, and perineal regions respectively. Distant non-genital warts were present in 16.2% of responders. Most patients (85.7%) didn't experience adverse effects of PPD injection Table 2.

Frequency distribution of the studied patients according to clinical response to PPD injection revealed that 37 patients (58.7%) completely recovered from warts and 26 patients (41.3%) didn't completely cure. Among male patients 22 patients (61.1%) were responders and among female patients, 15 patients (55.6%) were responders with no significant statistical relationship in between. Wart recurrence occurred in 23.3% of patients during the 3 months after complete cure, median recurrence time was 2.2 months Table 3.

The mean serum level of IL-17 in patients with genital warts was significantly lower ($P < 0.05$) than the control group, 81.1 ± 64.2 pg/mL versus 118.9 ± 93.8 pg/mL respectively. Mean serum level of IL-17 after PPD intralesional injection was significantly higher ($P < 0.05$) than before PPD intralesional injection, 107.1 ± 66.8 pg/mL versus

Table 1. Sociodemographic data of the studied patients and control group.

	Patients (n = 63)	Controls (n = 50)	χ^2	<i>P</i>
Age				
Mean \pm SD	30.8 ± 14.8	31.7 ± 12.9	$t = 0.2$	0.8
Range	20.4–50.7	18–48		
Sex				
Male	36 (57.1%)	30 (60%)	1.4	0.21
Female	27 (42.9%)	20 (40%)		
Marital status				
Single	8 (12.7%)	15 (30%)		
Married	50 (79.4%)	32 (64%)	2.4	0.078
Divorced	5 (8%)	3 (6%)		
Residence				
Urban	43 (63.4%)	35 (70%)	0.29	0.67
Rural	20 (36.6%)	15 (30%)		
Smoking				
Smokers	24 (39.7%)	19 (38%)	0.45	0.46
Non smokers	38 (61.9%)	31 (62%)		

χ^2 , chi-square test of significance. *t*, Student's *t* test of significance. Statistical significance at $P \leq 0.05$.

81.1 ± 64.2 pg/mL respectively (Figs. 1,2 and Table 4).

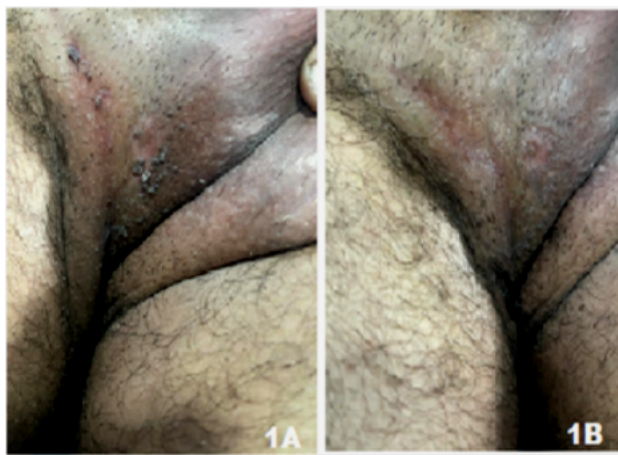


Fig. 1. A case of 32 years old male patient presented with genital warts on the perineal areas before and after PPD injection.

(A) a case of 32 years old male patient presented with multiple warts recurrent after electrosurgery from 3 months duration, located on the perineal area and upper thigh. Serum IL-17 level was 91.5 Pg/mL before PPD injection. (B) the same patient injected 10 tuberculin units' intralesionally every session for six sessions with 2 weeks interval. Complete removal was obtained without scarring. Serum IL-17 level was 132.6 Pg/mL after PPD injection.

The mean serum level of IL-17 after PPD injection was significantly higher ($P < 0.05$) in responders to PPD injection than non-responders, 118.54 ± 69.0 versus 95.9

Table 2. Frequency distribution of the studied patients according to genital warts characteristics (n = 63).

Duration of warts (Months)			
Min.–Max.	1.0–15.0		
Mean ± SD.	4.73 ± 5.07		
Number of warts			
Min.–Max.	2.0–45.0		
Mean ± SD.	9.76 ± 22.32		
Distribution of warts	N.	%	
External Genitalia	53	74.7%	
Pubic area	46	64.8%	
Perianal region	20	28.2%	
Perineum	14	19.7%	
Presence of distant non-genital warts in responders (n = 37)			
Present	6	16.2%	
Absent	31	83.3%	
Adverse reactions to PPD injection			
No adverse reaction	54	85.7%	
Adverse reaction	9	14.3%	
Adverse reactions to PPD injection			
Severe pain	9	100%	
Erythema	7	78%	
Hypopigmentation or hyperpigmentation	4	45%	
Systemic symptoms	4	45%	
Swelling	3	34%	

PPD, Purified Protein Derivative.

± 67.5 respectively. Mean serum level of IL-17 after PPD injection was higher in male responders to PPD injection than female responders 122.3 ± 78.1 pg/mL versus 110.7 ± 71.7 pg/mL respectively with an insignificant statistical relationship in between Table 5.

4. Discussion

HPV is a double-stranded DNA virus, with more than 200 different genotypes having been identified. This infection is considered the most common sexually transmitted disease and it causes different disease ranges including benign lesions (genital warts) and premalignant lesions and different cancers [16]. Genital warts cause marked affection of the quality of life of the affected person, sexual life and couple interpersonal communications are the most affected aspects [17].

Immunotherapy is a promising upcoming therapeutic line of management of numerous and difficult to treat genital warts as it can cause complete wart recovery with minimal injury, pain or scarring and relatively in short duration, as well as it improves the host immune reactivity against human papilloma virus, which leads to high little recurrence rates [18]. Immunotherapy is considered an economi-

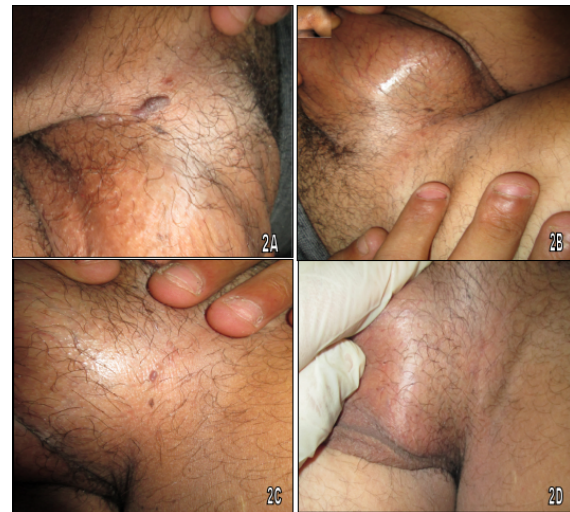

Fig. 2. A case of 36 years old male patient presented with genital warts on right and left groin areas before and after PPD injection. A case of 36 years old male patient presented with genital warts, located on the right and left groin areas. Before PPD injection, serum IL-17 level was 79.3 Pg/mL. After injection, serum IL-17 level was 110.3 Pg/mL. (A) Right groin warts before PPD injection, (B) complete removal of warts in right groin area after 6 sessions of PPD injection, 2 weeks interval, (C) Left groin warts before injection and (D) complete removal of warts in left groin area after PPD injection.

cal therapeutic modality for extensive neglected wart infections and subsequently can be of extraordinary incentive in developing countries [19].

In the current study, we used Immunotherapy with intralesional tuberculin PPD injection as a method of treatment of anogenital warts. Results revealed 37/63 patients (58.7%) were responders to PPD injection and 26/63 patients (41.3%) were not responders after 6 sessions of PPD injection. Male responders were more than female responders (61.1% versus 55.6% respectively with no significant statistical relationship in between.

These results were in concordance with Eassa and colleagues who used PPD as a novel method for treatment of genital warts in pregnant females and reported that 47.5% of patients showed complete cure, 37.5% had partial removal, 7.5% had minimal removal and 7.5% demonstrated no effect. Adverse effects were insignificant and minimal [20]. El Taieb *et al.* [21], reported that complete clearance of warts was observed in 43 patients (69.4%), partial response (25%–99% of warts cleared) was observed in 13 patients (20.9%) and no response (0–24% of warts cleared) was observed in 6 patients (9.7%), while Rajashekar *et al.* [19] found that complete clearance occurred in 35.3% of patients either on the injection site as well as anatomically distant sites, suggesting that response to PPD injection is a systemic response and not only restricted to the site of the injection. Singh *et al.* [8] also reported that out of 40 pa-

Table 3. Frequency distribution of the studied patients according to clinical response to PPD injection.

	Responders	Non-responders		
All Patients (n = 63)	37 (58.7%)	26 (41.3%)		
	Responders	Non-responders	<i>t</i>	<i>P</i>
Male patients (n = 36)	22 (61.1%)	14 (38.9%)	3.87	0.429
Female patients (n = 27)	15 (55.6%)	12 (44.4%)		
Response of distant warts (n = 6)		%		
Complete removal	4	66.7%		
No response	2	33.3%		
Recurrence after complete response (n = 37)				
No	28	76.7%		
Yes	9	23.3%		

PPD, Purified Protein Derivative. *t*, Paired *t*-test. *P*, *P* value for comparing between groups.

Table 4. Comparison between patients and control groups according to IL-17 serum level (pg/mL).

	Patients with genital warts	Control group	<i>t</i>	<i>P</i>
Interleukin 17 serum level (pg/mL)	Min.–Max.	21.8–176.9	36.4–278.6	
	Mean ± SD.	81.1 ± 64.2	118.9 ± 93.8	5.70 <0.05*
	Median	73	105	
	Patients before PPD injection	Patients after PPD injection	<i>t</i>	<i>P</i>
Interleukin 17 serum level (pg/mL)	Min.–Max.	21.8–176.9	26.8–208.5	
	Mean ± SD.	81.1 ± 64.2	107.1 ± 66.8	6.32 <0.05*
	Median	73	91	

PPD, Purified Protein Derivative. *t*, Paired *t*-test. *P*, *P* value for comparing between groups. *, Statistically significant at $P \leq 0.05$.

Table 5. Correlations between IL 17 serum level (pg/mL) and clinical response to PPD injection.

	Responders	Non-responders	F	<i>P</i>
Interleukin 17 serum level (pg/mL)	Min.–Max.	29.1–197.1	19.7–181.2	
	Mean ± SD.	118.54 ± 69.0	95.9 ± 67.5	4.87 0.032*
	Median	107	88	
	Male responders	Female-responders	F	<i>P</i>
Interleukin 17 serum level (pg/mL)	Min.–Max.	37.6–198.2	21.7–188.0	
	Mean ± SD.	122.3 ± 78.1	110.7 ± 71.7	1.99 0.754
	Median	115	104	

F, F for ANOVA test. *P*, *P* value for association between clinical response and serum IL-17 level. *, Statistically significant at $P \leq 0.05$.

tients, 32 patients (80%) showed complete recovery, 6 patients (15%) showed partial recovery, and 2 patients (5%) showed no response.

In the same line, Shaheen *et al.* [22] reported that PPD immunotherapy injection showed 60% clearance of target warts and distant warts with significant increase in circulating IL4. Nimbalkar *et al.* [18] was in agreement with our study as they found that out of 45 patients, 28 (62.2%) showed complete clearance, eight patients (17.8%) showed partial clearance, and nine patients (20%) showed no improvement. Abd-Elazeim *et al.* [23], evaluated serum level of interleukin 12 in common warts patients treated by intralesional PPD and found that complete response was

achieved in 75% of patients after 5.8 ± 0.7 sessions with a statistically significant increase of serum IL-12 level in PPD group than controls. Higher results were also reported by Elela *et al.* [24] who found that complete clearance was seen in 94.1% of the cases when intralesional PPD was administered in the wart tissue versus success rates of 96% the intradermal injection. Similarly, complete genital wart clearance was also reported after 3.29 sessions of PPD injection in 100% of patients in a study on 8 patients with genital warts. This was autonomous with the exceedingly significant increase ($P = 0.000$) in tissue levels of IL2 and IFN γ [25].

On the contrary Kus *et al.* [26] used intralesional tuberculin PPD injection in 18 patients with recalcitrant warts and found that complete cure was found in 5/18 patients (29%), partial response was found in 10/18 patients (59%) and no response was found in 2 (12%) patients. This cure rate is lower than the cure rate in our study and previously mentioned studies and this can be explained by small sample size, lower number of sessions, and wider interval of injections 3 weeks versus 2 weeks in our study.

Recently in 2020 Nofal *et al.* [27] studied the efficacy of intralesional tuberculin versus candida antigen in the management of refractory genital warts and reported a lower response rate of 32.1% in tuberculin group versus 41.3% in candida antigen group ($P > 0.05$).

In the current work, we measured the level of IL-17 in serum of patients with genital wart in comparison to the control group. The mean serum level of IL-17 was significantly higher ($P < 0.05$) in the control group than in the patients group (118.9 ± 93.8 pg/mL versus 81.1 ± 64.2 pg/mL) respectively.

This result was in agreement with Abu El-Hamd *et al.* [12] who measured the level of serum IL-17 and macrophage migration inhibitory factor (MIF) in patients with cutaneous warts including genital warts in comparison to control subjects. They found that serum levels of IL-17 and MIF were lower in patients with warts when compared to the controls. The mean serum level of IL-17 in patients with cutaneous warts was 89.4 pg/L while in the control group it was 123.44 pg/L with a significant difference in between.

In the same line, Ghanem *et al.* [13] evaluated IL-17 and zinc serum levels in recalcitrant warts. They found that a significant decrease in serum IL-17 and zinc levels in recalcitrant wart patients is present. Both IL-17 and zinc deficiency has a role in the pathogenesis of recalcitrant warts through the imbalance of the immune system and deficiency of immune cells. There was no significant correlation between serum levels of IL-17 and zinc, suggesting that they had different mechanisms in affecting the immune system.

Opposite results were reported by Bonin *et al.* [28] who studied IL-17 expression in the serum and exfoliated cervical cells of patients infected with high-risk oncogenic human papillomavirus (HR-HPV). They found that there was a significant increase in the concentration of IL-17 in HR-HPV-positive patients' serum when compared to that in samples of exfoliated cervical cells ($P < 0.05$). Likewise, when compared with that in healthy patients, the IL-17 concentration was still higher in HR-HPV-positive patients sera ($P < 0.05$). Their results suggested that HR-HPV infection predominantly stimulates systemic IL-17 production along with less localized expression. Such contradictory can be explained by the small sample size (26 patients and 18 controls) of Bonin study and the choice only of oncogenic genotypes of HPV which may have a different immunological trait than common HPV types.

Actual mechanisms of immunotherapy on HPV is not completely clear but it was suggested that Infiltration of CD4 T-lymphocytes and macrophages in wart tissues and stimulation of CD4 lymphocytes and increased release of Th1 cytokines such as IL-2, TNF- α , and IFN- α , β , and γ), leads to downregulation of gene transcription and activation of cytotoxic and natural killer cells that destroy the viral particles in treated sites as well as distant sites [29,30].

Based on the previous suggestion we tried to find out a possible explanation of the positive effect of PPD on genital warts through study of serum level of IL-17 in relation to PPD intralesional injection. We found that serum IL-17 level was significantly higher after injection of PPD than before PPD injection (107.1 ± 66.8 pg/mL versus 81.1 ± 64.2 pg/mL respectively). This denotes that intralesional PPD injection can cause some sort of upregulation of T helper cells with increased production of IL-17 which has a contributory role in HPV eradication. Serum IL-17 level in patients after 6 sessions of PPD injection was slightly lower ($P > 0.05$) than control group level. Mean serum level of IL-17 was significantly higher ($P < 0.05$) in responders to PPD injection than non-responders and also was higher in male responders to PPD injection than female responders but with insignificant statistical relationship in between. No available studies till now compared as in the current study, the relation between PPD injection and IL-17 level.

Limitations of the study were the small sample size which couldn't be generalized; Measurement of IL-17 in wart tissue if done would be more expressive to its relationship to genital wart activity or to PPD injection than serum level. Patient's compliance to repeated injection and waiting for three months to complete sessions of injection was very difficult due to abstinence of sexual act, pain of injection and fear from HPV complications so many patients were dropped off from follow up and excluded from the study and replaced by other patients. Partners of studied patients in most instants were not examined or assessed for presence or absence of genital warts which might cause poor response in some patients due to re-infection from infected partners. PPD was very sensitive to light and heat and could be easily spoiled if these factors were not controlled. We recommend measurement of other interleukins in wart patients either alone or concerning other therapeutic modalities especially immunotherapy on a larger sample size and in different therapeutic modalities.

5. Conclusions

Intralesional PPD injection in genital wart patients is an effective minimally invasive, safe, economic modality of treatment especially with numerous or resistant warts. IL-17 serum level is significantly lower in genital wart patients than control subjects without genital warts. IL-17 serum level is increased significantly after PPD intralesional injection than pretreatment levels and significantly related to clinical response to PPD.

Abbreviations

PPD, Purified Protein Derivative; IL-17, Interleukin 17; HPV, Human Papilloma Virus; ELISA, Enzyme Linked Immunosorbent Assay.

Author contributions

MA, MME, EROA & HAEN planned and designed the study. HAEN & MA supported considerable contributions to the study conception and design. MME, EROA & MA collected the data. MME, EROA, MA & HAEN implemented the clinical part and investigations. MME and EROA analyzed and interpreted the data. MA drafted the article. All authors read and approved the final manuscript.

Ethics approval and consent to participate

This study was approved by the Institutional Review Board and the Ethics Committee of Suez Canal University. Ethical Committee approval number was 3487; date 9/4/2018. All patients signed an informed consent contained rationale, aim, objectives, methodology, expected side effects and benefits of the study.

Acknowledgment

The authors wish to express their marked gratitude and thanks to all members of Dermatology, Venerology and Andrology department, Suez Canal University for their support and help in data collection and to all participants in the study.

Funding

This research received no external funding.

Conflict of interest

The authors declare no conflict of interest.

References

- [1] Leslie SW, Kumar S. Genital Warts. In StatPearls. Treasure Island (FL): StatPearls Publishing. 2019.
- [2] Leung AK, Barankin B, Leong KF, Hon KL. Penile warts: an update on their evaluation and management. *Drugs Context*. 2018; 7: 212563.
- [3] Abdullah AN, Walzman M, Wade A. Treatment of external genital warts comparing cryotherapy (liquid nitrogen) and trichloroacetic acid. *Sexually Transmitted Diseases*. 1993; 20: 344–345.
- [4] Baigrie D, Qafiti FN, Buicko JL. Electrosurgery. In StatPearls. Treasure Island (FL): StatPearls Publishing. 2020.
- [5] On SC, Linkner RV, Haddican M, Yaroshinsky A, Gagliotti M, Singer G, *et al*. A single-blinded randomized controlled study to assess the efficacy of twice daily application of sinecatechins 15% ointment when used sequentially with cryotherapy in the treatment of external genital warts. *Journal of drugs in dermatology*. 2014; 13: 1400–1405.
- [6] Jung JM, Jung CJ, Lee WJ, Won CH, Lee MW, Choi JH, *et al*. Topically applied treatments for external genital warts in nonimmunocompromised patients: a systematic review and network meta-analysis. *British Journal of Dermatology*. 2020; 183: 24–36.
- [7] Choi H. Can quadrivalent human papillomavirus prophylactic vaccine be an effective alternative for the therapeutic management of genital warts? An exploratory study. *International Brazilian Journal of Urology*. 2019; 45: 361–368.
- [8] Singh M, Thakral D, Kar HK, Rishi N, Sharma PK, Mitra DK. Distinct clinico-immunological profile of patients infected with human papilloma virus genotypes 6 and 11. *VirusDisease*. 2017; 28: 200–204.
- [9] Mohamed EEM, El Taieb MA, Abd El- sabour GA. Intralesional Vitamin D3 versus Purified Protein Derivatives in the Treatment of Multiple Cutaneous Warts: Comparative Study. *The Egyptian Journal of Hospital Medicine*. 2019; 76: 3589–3594.
- [10] Leiding JW, Holland SM. Warts and all: human papillomavirus in primary immunodeficiencies. *The Journal of Allergy and Clinical Immunology*. 2013; 130: 1030–1048.
- [11] Song X, Qian Y. The activation and regulation of IL-17 receptor mediated signaling. *Cytokine*. 2013; 62: 175–182.
- [12] El-Hamd MA, Assaf HA, Nada EA. Possible role of interleukin-17 and macrophage migration inhibitory factor in cutaneous warts. *Journal of Cosmetic Dermatology*. 2019; 17: 1250–1253.
- [13] Ghanem AH, Esawy AM, Khalifa NA, Kamal HM. Evaluation of serum interleukin 17 and zinc levels in recalcitrant viral wart. *Journal of Cosmetic Dermatology*. 2020; 19: 954–959.
- [14] Nayak S, Acharjya B. Mantoux test and its interpretation. *Indian Dermatology Online Journal*. 2012; 3: 2–6.
- [15] Choudhary D, Piya S. Treatment of Warts by Immunotherapy using Purified Protein Derivative. *Birat Journal of Health Sciences*. 2018; 3: 463–467.
- [16] Sendagorta-Cudós E, Burgos-Cibrián J, Rodríguez-Iglesias M. Genital infections due to the human papillomavirus. *Enfermedades Infecciosas Y Microbiología Clínica*. 2019; 37: 324–334.
- [17] Lynch MD, Cliffe J, Morris-Jones R. Management of cutaneous viral warts. *British Medical Journal*. 2014; 348: g3339.
- [18] Nimbalkar A, Pande S, Sharma R, Borkar M. Tuberculin purified protein derivative immunotherapy in the treatment of viral warts. *Indian Journal of Drugs in Dermatology*. 2016; 2: 19.
- [19] Rajashekar TS, Amulya R, Sathish S, Kumar S. Comparative study of intralesional BCG and PPD in the treatment of multiple cutaneous warts. *Indian Journal of Clinical and Experimental Dermatology*. 2018; 2018: 1–6.
- [20] Eassa BI, Abou-Bakr AA, El-Khalawany MA. Intralesional injection of PPD as a novel approach of immunotherapy in anogenital warts in pregnant women. *Dermatologic Therapy*. 2011; 24: 137–143.
- [21] Mohamed EEM, El Taieb MA, Abd El- sabour GA. Intralesional Vitamin D3 versus Purified Protein Derivatives in the Treatment of Multiple Cutaneous Warts: Comparative Study. *The Egyptian Journal of Hospital Medicine*. 2019; 76: 3589–3594.
- [22] Shaheen MA, Salem SAM, Fouad DA, El-Fatah AAA. Intralesional tuberculin (PPD) versus measles, mumps, rubella (MMR) vaccine in treatment of multiple warts: a comparative clinical and immunological study. *Dermatologic Therapy*. 2016; 28: 194–200.
- [23] Abd-Elazeim FMA, Mohammed GFA, Fathy A, Mohamed RW. Evaluation of IL-12 serum level in patients with recalcitrant multiple common warts, treated by intralesional tuberculin antigen. *The Journal of Dermatological Treatment*. 2014; 25: 264–267.
- [24] Elela I, Elshahid AR, Mosbeh AS. Intralesional vs intralesional purified protein derivatives in treatment of warts. *The Gulf Journal of Dermatology and Venerology*. 2011; 18: 21–26.
- [25] Youssef SS, Diab H, Sallam MN, Ahmed A. Evaluation of IL-2, IFN-gamma mRNA gene expression in resistant genital and plantar warts, treated by intralesional tuberculin. *Pan Arab League of Dermatologists*. 2009; 20: 147–158.

- [26] Kus S, Ergun T, Gun D, Akin O. Intralesional tuberculin for treatment of refractory warts. *Journal of the European Academy of Dermatology and Venereology*. 2005; 19: 515–516.
- [27] Nofal A, Soliman M, Hamdy F, Alakad R. Intralesional Candida antigen versus intralesional tuberculin in the treatment of recalcitrant genital warts: a comparative study. *Journal of the American Academy of Dermatology*. 2020; 82: 1512–1514.
- [28] Mareti Bonin C, Zatorre Almeida-Lugo L, Rodrigues dos Santos A, Tezelli Junqueira Padovani C, Silva Pina AF, Teixeira Ferreira AM, *et al.* Interleukin-17 expression in the serum and exfoliated cervical cells of patients infected with high-risk oncogenic human papillomavirus. *Cytokine*. 2019; 120: 92–98.
- [29] Maronn M, Salm C, Lyon V, Galbraith S. One-year experience with candida antigen immunotherapy for warts and molluscum. *Pediatric Dermatology*. 2008; 25: 189–192.
- [30] Nofal A, Nofal E, Yosef A, Nofal H. Treatment of recalcitrant warts with intralesional measles, mumps, and rubella vaccine: a promising approach. *International Journal of Dermatology*. 2015; 54: 667–671.